[5] Deng YB, Masayuki M, Satoshi T, et al. Ultrasonic evaluation of endothelial function in hypertensive elderly[J]. Chinese J Ultrasonogr Med, 1999, 15(7): 504-506.
邓又斌,松本正幸,潼泽哲,等.老年高血压患者内皮功能的超声显像法研究[J].中国超声医学杂志,1999,15(7):504-506.

[6] Perticone F, Maio R, Ceravolo R, et al. Relationship between left ventricular mass and endothelium-dependent vasodilation in never-treated hypertensive patients[J]. Circulation, 1999, 99(15): 1991-1996.

[7] Kawasaki T, Sasayama S, Yagi S, et al. Non-invasive assessment of the age related changes in stiffness of major branches of the human arteries[J]. Cardiovascular Res, 1987, 21(9): 678-687.

[8] Yamashina A, toyiyama H, Arai T, et al. Nomogram of the relation of brachial-ankle pulse wave velocity with blood pressure[J]. Hypertens Res, 2003, 26(10): 801-806.

[9] Munakata M, Ito N, Nunokawa T, et al. Utility of automated brachial ankle pulse wave velocity measurements in hypertensive patients[J]. Am J Hypertens, 2003, 16(8): 653-657.

[10] Pasierski TJ, Binkley PF, Pearson AC, et al. Evaluation of aortic distensibility with transesophageal echocardiography[J]. Am Heart J, 1992, 123(5): 1288-1292.

[11] Arnett DK, Boland LL, Evans GW, et al. Hypertension and arterial stiffness: the atherosclerosis risk in communities study. ARIC investigator[J]. Am J Hypertens, 2000, 13(4 pt 1): 317-323.

[12] Ghiadoni L, Huang Y, Magana A, et al. Effect of acute blood pressure reduction on endothelial function in the brachial artery of patients with essential hypertension[J]. J Hypertens, 2001, 19(3 pt 2): 547-551.

[13] Mu NN, Liang CX, Liu JP, et al. Evaluation of brachial artery endothelial function in early-stage essential hypertension[J]. Chin J Med Imaging Technol, 2003, 19(2): 181-182.
牟楠楠,梁春香,刘建平,等.早期高血压肱动脉内皮功能研究[J].中国医学影像技术,2003,19(2):181-182.

[14] Perticone F, Maio R, Ceravolo R, et al. Relationship between left ventricular mass and endothelium-dependent vasodilation in never-treated hypertensive patients[J]. Circulation, 1999, 99(15): 1991-1996.

Variance of cornu superius cartilagenis thyroidease: case report

甲状软骨上角变异1例

李思源,吴新淮,李珍红,何茂佐,李　兵

(北京军区总医院263临床部放射科,北京　101149)

[**Key words**] Thyroid cartilage; Variation　[**关键词**] 甲状软骨;变异

[**中图分类号**] R681.3　[**文献标识码**] B　[**文章编号**] 1003-3289(2005)04-0582-01

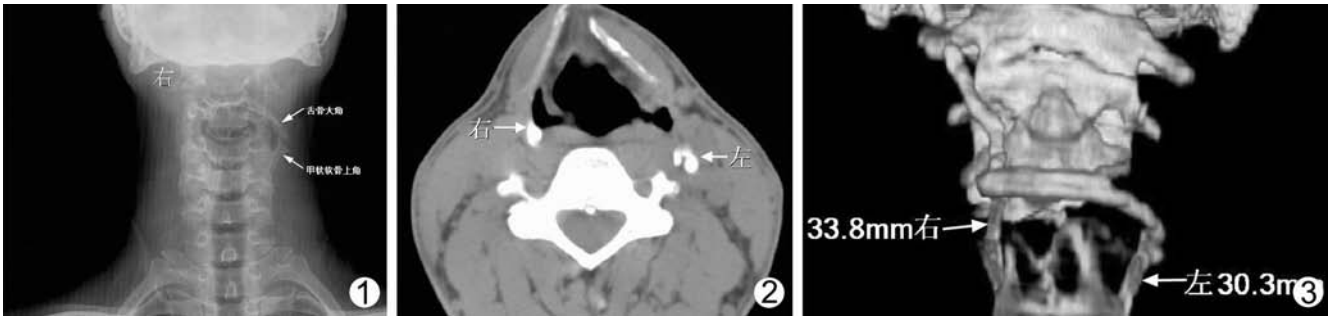

图1～3　甲状软骨上角与舌骨形成假关节

患者男,40岁,咽部不适、异物感7年,曾诊断为"慢性咽喉炎",因颈部挤压伤,感觉咽喉部疼痛、不适及异物感加剧到本院就诊。平片发现颈4～6椎体左侧细条形骨性密度影,上方与舌骨相连,并构成假关节(图1)。颈部螺旋CT薄层扫描,行4D重建,发现甲状软骨大部骨化,双侧甲状软骨上角过长,右侧长约33.8 mm,左侧长约30.3 mm,清晰显示与双侧舌骨大角形成的假关节,诊断为甲状软骨骨化并双侧上角过长变异(图2,3)。

讨论　据调查,汉族成年男性的甲状软骨上角长径为右侧10.00～22.50 mm,平均14.11 mm,左侧7.90～21.00 mm,平均14.71 mm;汉族成年女性的甲状软骨上角长径为右侧8.00～18.10 mm,平均12.66 mm,左侧9.50～17.80 mm,平均13.49 mm。甲状软骨上角长径超过上述最大值者即为过长。甲状软骨上角的解剖变异可能刺激颈动脉、颈交感神经干上段、舌骨大角等,造成舌骨综合征等相应症状。临床有咽喉不适、异物感主诉时,应通过X光片及CT与本病鉴别。本病的治疗方法是在颈丛麻醉下经颈侧径路切除过长之甲状软骨上角。

[**作者简介**] 李思源(1979－),男,河北燕郊人,本科,医师。

[**收稿日期**] 2005-01-09　[**修回日期**] 2005-03-02